

Case report

Possible effects of pramipexole on neck muscles in a patient with Parkinson's disease

Roberto Filippi^{1,*}, Mario Rasetti², Marco Lenzi³ and Peter Bright¹

¹Anglia Ruskin University, Cambridge, UK, ²FMSI Federazione Medico Sportiva Italiana, Medicina Sportiva, Livorno, Italy and ³Centro di Fisioterapia FISIOS, Livorno, Italy

*Correspondence address. Department of Psychology, Faculty of Science and Technology, Anglia Ruskin University, East Road, CB1 1PT Cambridge, UK. Tel: +44 (0)1223 363271; E-mail: roberto.filippi@anglia.ac.uk

Received 3 February 2014; revised 28 February 2014; accepted 2 March 2014

Recent case reports suggest a possible causal correlation between antecollis and pramipexole. Here, we report the case of a 62-year-old Italian man with a 2-year history of Parkinson's disease (PD) and cervical spondylosis for which he was treated with pramipexole. He developed severe neck rigidity immediately after an inguinal hernia operation but several months after introduction of pramipexole. He was initially treated with painkillers and physiotherapy with no significant improvement. His condition deteriorated presenting disproportionate rigidity between anterior and posterior neck muscles (antecollis) to the extent that normal activities were severely restricted. However, significant improvement occurred after the withdrawal of pramipexole. The patient undertook a second cycle of physiotherapy with remarkable results and returned to function normally in everyday life. This case report suggests that neurologists should be motivated to inform the scientific community about other possible cases in which an association between antecollis and pramipexole might operate in PD.

INTRODUCTION

Parkinson's disease (PD) is an idiopathic progressive neurological condition associated with degeneration of dopaminergic neurons in the substantia nigra, resulting in dopamine loss in the striatum. Prevalence statistics vary widely but a meta-analysis of US and European studies suggests ~1% of those aged over 65 suffer from the disease [1]. Common motor deficits (bradykinesia, muscle rigidity and tremor) typically improve with dopaminergic replacement therapy.

Pramipexole is a dopamine receptor agonist used to treat PD, particularly in its early stages. A number of studies have indicated continued efficacy of the treatment for up to 4 years while identifying potentially severe side effects such as dyskinesia, asymptomatic orthostatic hypotension and nausea [2, 3]. A small number of recent PD cases have identified a possible link between pramipexole and the development of antecollis (marked neck flexion, disproportionate to trunk flexion) with recovery apparently contingent upon the withdrawal of treatment [4, 5].

CASE REPORT

A 62-year-old Italian man developed slowness and loss of strength of his right arm and hand. In July 2010, after a first neurological examination, he was prescribed L-DOPA, 250 mg/day, resulting in significant improvement of his parkinsonism. PD was therefore indicated using an *ex juvantibus* reasoning. Subsequent magnetic resonance imaging carried out in October 2010 excluded other conditions. At this point, the diagnosis of PD was confirmed and the neurologist who followed the patient at that time made the decision to change treatment to 1.05 mg/day of pramipexole and the complete cessation of L-DOPA. He was checked twice over a period of 12 months and his condition was considered stable each time.

The patient had a history of cervical spondylosis, a very common condition in the aging population caused by the progressive degeneration of the neck bones and neck tissues. He also had a straightforward inguinal hernia for which he undertook a corrective operation on 21 November 2011. The operation started at 9:00 am and ended at ~9:30 am. He did not take pramipexole on the day of the operation. Given the option of

general anesthesia or epidural he chose the former, carried out as follows:

- Stage 1: Analgesic administration: [ultiva (remifentanyl); infusion pumps were used]
- Stage 2: Anesthesia induction: (propofol and curare immediately after)
- Stage 3: Intubation: [halogenated anesthetic (sevorane)];
- Stage 4: Before wake up: prostigmina was used to eliminate curare and sevorane was stopped.

There were no postoperative complications and the patient was discharged on the same day. He restarted taking pramipexole (1.05 mg) on the morning after the operation. On the same day, he developed neck rigidity and his head dropped forward. The local general practitioner treated him with painkillers, but these proved ineffective.

From the immediate onset of antecollis the patient's life was severely impaired: he needed assistance at work, could not drive his car and experienced difficulties when eating and speaking. On 3 April 2012, the patient decided to consult a professional physiotherapist who objectively confirmed severe antecollis: his neck was bent forward at an angle of 80–90°. He could actively extend his head up only of about 50–40° with obvious compensation of the posterior and inferior (lumbar) muscles of the vertebral trunk. Therefore, this was not a real extension of the head and could not be sustained beyond ~30 s. The neck rotation on both left and right sides of the head was severely restricted. He undertook 10 physiotherapy sessions with the aim of reducing the strong contraction of his neck muscles. However, no improvement was observed on treatment completion.

In June 2012, 6 months from the onset of antecollis, following similar cases reported in the literature [4, 5], it was decided to withdraw pramipexole and reintroduce L-DOPA. The improvement was almost immediate: on the first day, the patient felt less pressure on the neck and gained more flexibility. After a few days, he could easily turn his neck and he started to drive his car again.

On 13 August 2012, about 2 months after the cessation of pramipexole, the patient decided to undertake a second cycle of physiotherapy. His condition objectively appeared significantly improved, despite the extended period of time in which his neck movements were severely impaired. The only change in his treatment regime from June to August 2012 was the cessation of pramipexole.

Since this second cycle of physiotherapy, neck angle remained about 30° at rest. The patient can now perform extension and rotation movement easily, as shown in Fig. 1.

Unlike the cited cases in which antecollis appeared within a few weeks after taking pramipexole, this patient developed antecollis several months after its introduction for the treatment of PD. This relatively extended period might indicate that some factor(s) other than pramipexole may have induced antecollis, but the improvement upon cessation suggests otherwise. Intriguingly, antecollis emerged immediately after the inguinal hernia operation, raising the possibility that onset

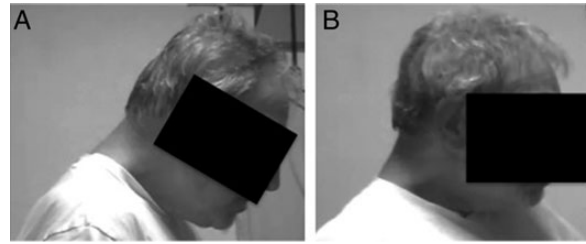


Figure 1: A 62-year-old patient with Parkinson's disease who developed antecollis following treatment with pramipexole (1.05 mg/day) showing: (A) prominent antecollis in an upright position during treatment with pramipexole and (B) improvement of antecollis after withdrawal of the pramipexole treatment.

was triggered by the surgical procedure—however, this interpretation is highly speculative.

DISCUSSION

We report the case of a PD patient who received ~1-year treatment with pramipexole with no evident side effects, and developed antecollis after an inguinal hernia operation. Physiotherapy did not improve the condition, and ultimately a decision was implemented to cease pramipexole and reintroduce L-DOPA. This change of medication improved his antecollis and allowed him to return to his normal life habits. The patient had a history of cervical spondylosis but had never suffered from muscle rigidity before PD was diagnosed or between diagnosis and his hernia operation.

Claims for a relationship between antecollis and pramipexole have been reported in the literature [4, 5]. In this case report, however, the connection is complicated by the extended delay between the introduction of pramipexole and the onset of antecollis. Nevertheless, the antecollis showed dramatic improvement once pramipexole was withdrawn. Moreover, we tentatively raise the possibility that anesthesia (in this case prior to an inguinal hernia operation) might interact in some way with pramipexole to encourage the onset of antecollis. However, given the rate at which the effects of general anesthetics abate and the chemicals are 'washed-out', a viable explanation for such a link is difficult to envisage. The neck positioning during intubation could also have played a role. However, we suggest that this is unlikely given the short duration of the surgical procedure (~30 min).

In conclusion, further investigation is needed to determine with confidence the relationship between pramipexole and antecollis in PD. This case report suggests that neurologists should be motivated to inform the scientific community about other possible cases of PD in which an association between antecollis and pramipexole might operate.

REFERENCES

1. Hirtz D, Thurman DJ, Gwinn-Hardy K, Mohamed M, Chaudhuri AR, Zalutsky R. How common are the 'common' neurologic disorders? *Neurology* 2007;**68**:326–37.

2. Möller JC, Oertel WH, Köster J, Pezzoli G, Provinciali L. Long term efficacy and safety of pramipexole in advanced Parkinson's disease: results from a European multicenter trial. *Mov Disord* 2005;**20**:602–10.
3. Weiner WJ, Factor SA, Jankovic J, Hauser RA, Tetrud JW, Waters CH, et al. The long-term safety and efficacy of pramipexole in advanced Parkinson's disease. *Parkinsonism Relat Disord* 2001;**7**:115–20.
4. Kim HJ, Jeon BS, Kim HS, Han S-H. Reversible antecollis associated with pramipexole in a patient with Parkinson's disease. *J Clin Neurosci* 2012;**19**:903–4.
5. Suzuki M, Hirai T, Ito Y, Sakamoto T, Oka H, Kurita A, et al. Pramipexole-induced antecollis in Parkinson's disease. *J Neurol Sci* 2008;**264**:195–7.